



Abdominal localization of unicentric form of Castleman disease – A case report

Unicentrična forma Kastlemanove bolesti lokalizovane u stomaku

Boško Milev^{*†}, Borka Milev[‡], Zoran Kostić^{*†}, Darko Mirković^{*†}, Nenad Perišić[§],
Olga Tasić^{||}, Marija Elez[¶], Aleksandar Radunović^{**}, Milan Jovanović^{*†}, Predrag
Marić^{††}, Sanja Daišević^{‡‡}, Rade Prelević^{††}, Maja Vulović^{‡‡}

^{*}Clinic for General Surgery, [§]Clinic for Gastroenterology and Hepatology, ^{||}Institute of Pathology and Forensic Medicine, [¶]Clinic for Hematology, ^{**}Clinic for Orthopedic Surgery, ^{††}Clinic for Urology, Military Medical Academy, Belgrade, Serbia; [†]Faculty of Medicine of the Military Medical Academy, University of Defence, Belgrade, Serbia; [‡]Clinic for General and Thoracic Surgery, Kragujevac, Clinical Center Kragujevac, Serbia; ^{‡‡}Department of Anatomy and Forensic Medicine, Faculty of Medical Sciences, University of Kragujevac, Kragujevac, Serbia

Abstract

Introduction. Castleman disease is a rare disease of the unknown etiology, occurring in two clinical forms: unicentric or multicentric. It is characterized by the hyperplasia of lymph glands. In literature the four pathohistological forms were described: hyaline vascular type, plasma cell type, mixed type and a recently recognized plasmablastic type. The most frequent changes are localized in the mediastinum, while the abdominal localization is with significantly rare occurrence, and that was the motive for presentation of this case. **Case report.** In a 41-year old male magnetic resonance (MR) enterography showed a change in the ileocecal area without the presence of subjective symptoms of digestive tract and without loss of body mass. Due to the suspicion of stromal tumor, surgical intervention was indicated. Pathohistological findings showed Castleman *lymphadenopathia reactiva mesenterii* (plasma cell type) which was in the unicentric form. There were present only anaemia and the increased value of sedimentation from the laboratory analyses. **Conclusion.** Abdominal localization of unicentric plasma cell form occurs rarely and the surgical method of treatment presents the golden standard as it was shown in the presented case.

Key words:

giant lymph node hyperplasia; cecum; diagnostic techniques and procedures; diagnosis, differential; lymph nodes; digestive system surgical procedures.

Apstrakt

Uvod. Kastlemanova bolest je retko oboljenje nepoznate etiologije koje se javlja u dve kliničke forme: unicentrična ili multicentrična. Odlikuje se hiperplazijom limfnih žlezda. U literaturi se opisuju četiri patohistološka oblika: hijalinovaskularni tip, plazmocitni tip, mešoviti tip i skorije prepoznat plazmablastični tip. Promene su najčešće lokalizovane u medijastinumu, dok se abdominalna lokalizacija znatno ređe javlja, što je i bio razlog za ovaj prikaz slučaja. **Prikaz bolesnika.** Kod muškarca, starog 41 godinu, na magnetnoj rezonantnoj (MR) enterografiji uočena je promena u ileocekalnoj regiji bez prisustva subjektivnih simptoma iz digestivnog trakta kao i bez gubitka telesne mase. Zbog sumnje na stromalni tumor, indikovana je hirurška intervencija. Patohistološki nalaz je pokazao Kastlemanovu *lymphadenopatija reactiva mesenterii* (plazma-čelijski tip) u unicentričnoj formi. Od laboratorijskih analiza jedino su bile prisutne anemija i ubrzana sedimentacija eritrocita. **Zaključak.** Abdominalna lokalizacija unicentrične plazmocitne forme Kastlemanove bolesti javlja se retko, a hirurška metoda lečenja predstavlja zlatni standard što je potvrđeno ovim prikazom.

Ključne reči:

kastlemanova bolest; cecum; dijagnostičke tehnike i procedure; dijagnoza, diferencijalna; limfne žlezde; hirurgija digestivnog sistema, procedure.

Introduction

Castleman disease (CD) is a rare, benign disease characterized by the lymph node hyperplasia. It was described

for the first time by Castleman and Towne¹ in 1954, but its etiology has not been completely solved yet. In literature other names for this disease were mentioned: giant lymph node hyperplasia, angiofollicular lymph node hyperplasia, lymph no-

de hamartoma, and benign lymph node lymphoma². CD occurs in four pathohistological forms: hyaline-vascular type, plasmacell type, mixed type and recently recognized plasmablastic type³. Depending on the lymph node degree of affection, it could have two clinical forms: unicentric or multicentric. Changes are often localized in the mediastinum (65%) while in other parts their incidence is less: in the neck (16%), abdomen (12%), axilla (3%)^{4,5}. This paper presented a patient with abdominal localization of unicentric form of CD, analysis of clinical picture, diagnostic procedures and treatment.

Case report

A 41-year-old male submitted to diagnostic procedures for the last two years due to sideropenic anaemia, was hospitalized at the Clinic for Gastroenterology and Hematology, Military Medical Academy, Belgrade, for the clarification of changes in the area of terminal ileum, seen at magnetic resonance (MR) enterography. The patient denied the presence of pain in abdomen, loss of body mass, as well as difficulties of the upper parts of digestive tract. By laboratory analyses the following values were determined: sedimentation rate of erythrocytes (SE) – 51 mm/h, C-reactive protein (CRP) – 24.9 mg/L; fibrinogen – 5.6 mg/dL, leukocytes (Le) – $6.41 \times 10^9/L$; hematocrit (Ht) – 0.42, thrombocytes (Tr) – $287 \times 10^9/L$. Physical findings of the abdomen were without pathological changes. Auscultatory findings in lungs with no abnormalities detected. There were no signs of peripheral lymphadenopathy. On MR imaging there was a circular, clearly limited, well vascularized solid change in the ileocecal area, 34×37 mm in diameter which was not clearly separated

from the ileum gyri. Other procedures performed were scintigraphy on Meckel diverticulum, colonoscopy, esophagogastroduodenoscopy (EGD) and radiography (RTG) of the lungs, showing no pathological changes. Echo of the abdomen showed calculosis of gallbladder. Due to the suspicion of stromal tumor of the abdomen, surgical intervention was indicated. After preoperative preparation, surgical intervention was performed: *Resectio intestini ilei terminaliss cum ileo-caeco anastomosis latero-lateralis*, cholecystectomy, appendectomy. Intraoperative findings was as follows: in the area of meso terminal ileum on roughly 35 cm from the valvula Bauhini, a ball-like, solid tumefaction, 7×6 cm in diameter, was found, performing compression to the part of ileum wall and narrowing its lumen. Tumor change on one side elevates the peritoneum and protrudes beneath the meso terminal ileum surface, on the other side unclearly and restrictedly compresses it (Figures 1 and 2).

Directly under this tumor change the enlarged lymph gland was noticed, which together with the tumefaction was sent to pathohistological analysis. Postoperative course was normal, with the wound which healed *per primam* and established an intestinal passage.

Pathohistological findings indicated Castleman *lymphadenopathia reactiva mesenterii* (plasma cell type). Tumor-like enlarged lymph nodus in meso ileum of the small intestine was thick with numerous follicles, irregularly large, reactive germinal centers (Bcl2), with the presence of IgD mantle cell zone, as well as many thin follicles of the involution appearance, of the concentric thin cell mantle zone, without visible hyalinosis of blood vessels in these germinal centers (except one) (Figures 3 and 4).

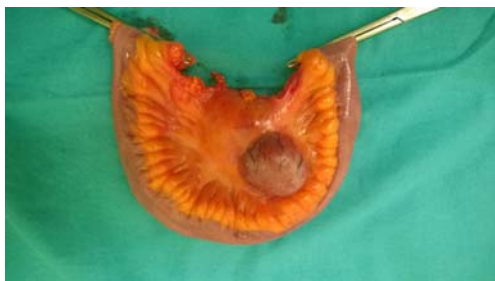

Fig. 1 – A removed part of the terminal ileum with a tumor *in meso* ileum – front view.

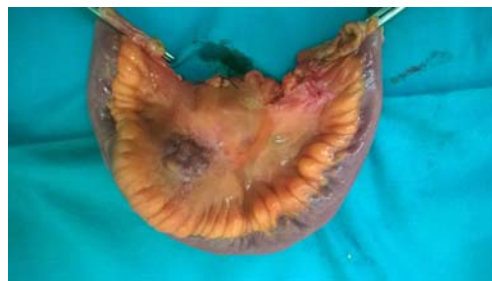

Fig. 2 – A removed part of the terminal ileum with a tumor *in meso* ileum – rear side.

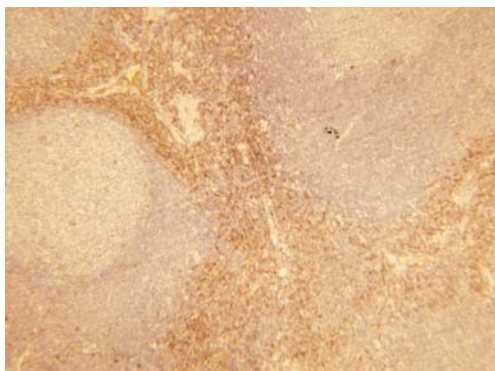


Fig. 3 – CD 138, plasma cells interfollicular (CD 138 immunostain, $\times 40$).

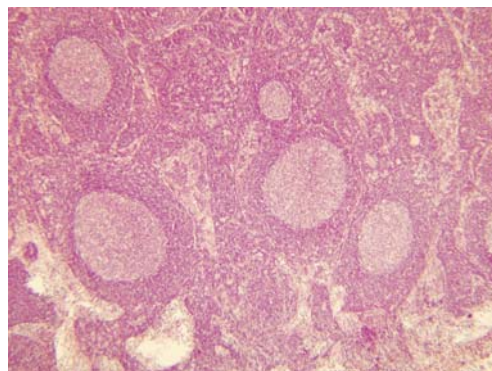


Fig. 4 – Primary follicular structures with interfollicular distension. Blood vessels and mass of plasma cell (HE, $\times 40$).

Interfollicularly, the massive plasmocytosis was present (CD138+/Kappa+/lambda+) with numerous Russell bodies with rare individual CD20+/PAX5+/Bcl 6-, as well as the copious and noticeable vascular postcapillary proliferation of blood vessels with thickening of hyaline walls (Figures 5 and 6). An enlarged lymph node (the reactive lymphadenopathy) was found.

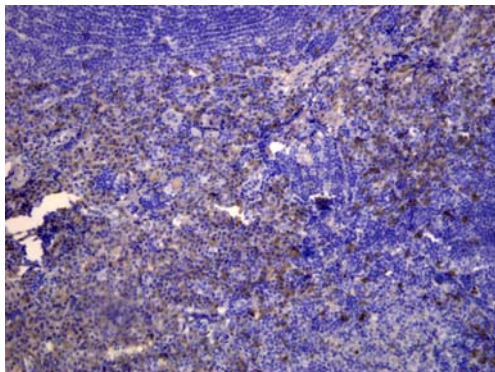


Fig. 5 – Intracytoplasmic kappa light chains in plasma cells (Kappa staining reagent system, ×200).

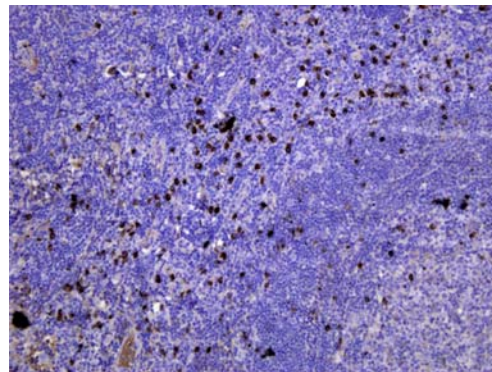


Fig. 6 – Intracytoplasmic lambda light chains in plasma cells (Lambda staining reagent system, ×200).

Discussion

Clinical manifestation and symptoms of CD are various depending on the disease type. They can be absent in some cases while in others they can be various and related to the infection, autoimmune disease or some tumor forms. In the localized, unicentric form, an enlarged lymph node if it is localized in the abdomen, could be asymptomatic and found by chance, as it was in the presented patient. Most often symptoms in unicentric, plasma cell form are anaemia, high value of SE, thrombocytopenia, hyperglobulinemia, splenomegaly, night perspiration, loss of weight, exhaustion^{5,6}. In the presented patient, as the dominant findings, a 2-year anaemia and increased SE were present, but other laboratory parameters were in the normal limits.

CD occurs in adult persons and children, more often in the unicentric form. The first case with this disease was described by Dr. Benjamin Castleman at patients with the hyperplastic mediastinal lymph node classifying it as the unicentric form¹.

The multicentric form is related to viral infections. Researches show the presence of human herpesvirus 8 (HHV-8) or Kaposi sarcoma herpesvirus (KSHV) in lymph nodes in patients with multicentric forms, and this form occurs most often in persons with HIV infection³.

The diagnosis of CD can be made by pathohistological findings. The first patient with CD, with the dominance of plasma cells, was operated in 1969, and classification of CD to the hyaline vascular and plasma cell histopathological type was done by Keller et al.⁷ in 1972. In some papers classification of pathological changes is performed based on the localization, *ie* spreading of changes, so the unicentric form includes the hyaline vascular and plasma cell variant while at

multicentric form the plasma cell type is dominant with the occurrence of plasmablastic characteristics⁸. Most recent recommendations of the American Cancer Society classify CD in 4 forms. Above mentioned researches showed that the unicentric plasma cell form occurred in 10–20% of patients and more often in younger patients (in the third and the fourth decade of life) and hyaline-vascular type, the most

frequent, was described with the incidence of 70–90%^{1,8–10}. In the plasma cell form of the disease, pathohistological findings show the hyperplastic germinal center with a vascularized interfollicular part of the node and leaves of the polyclonal plasma cells. This histological findings are not specific only for CD, but it can be found also at hyperplastic reactive lymph nodes, for example at rheumatoid arthritis and viral lymphadenitis^{8,11}.

The most frequent localization of the unicentric form is the mediastinum, and in the abdomen and the pelvis it was described as the focal mass differently localized: as retroperitoneal mass, in the mesentery, *porta hepatis* and in the pancreas⁵.

CD treatment depends on the form of the disease and histological type. Surgical mode of unicentric form treatment is supposed to be the gold standard and it offers excellent results in over 90% of cases^{12–14}. When lymph nodes could not be completely removed or when the surgical intervention is contraindicated, radiotherapy is used². In the presented patient, surgical procedure led to the restoration of health, taking into consideration that additional diagnostic methods like positron emission tomography (PET) scan of the thorax and abdomen, did not suggest any pathological changes. In the multicentric form other modes of treatment are also applied: chemotherapy, application of corticosteroids, antiviral and immunomodulatory therapy¹¹.

Conclusion

Abdominal localization of the unicentric plasma cell form of Castleman disease has a small incidence, and the surgical method of treatment represents the gold standard as it was confirmed by the presented patient.

R E F E R E N C E S

1. *Castleman B, Towne VW*. Case records of the Massachusetts General Hospital: Case No. 40231. *N Engl J Med* 1954; 250(23): 1001–5.
2. *Seirafi PA, Ferguson E, Edwards FH*. Thoracoscopic resection of Castleman disease: Case report and review. *Chest* 2003; 123(1): 280–2.
3. American Cancer Society. 2014. Available from: <http://www.cancer.org/cancer/castlemandisease/detailedguide/index>
4. *Boovalli MM, Raju K, Venkataramappa SM*. Castleman's disease of the mesocolon: A rare case report. *Biomed Res Ther* 2014; 1(3): 93–7.
5. *Cronin DM, Warnke RA*. Castleman disease: An update on classification and the spectrum of associated lesions. *Adv Anat Pathol* 2009; 16(4): 236–46.
6. *Meador TL, McLarney JK*. CT features of Castleman disease of the abdomen and pelvis. *AJR Am J Roentgenol* 2000; 175(1): 115–8.
7. *Keller AR, Hochbolzger L, Castleman B*. Hyaline-vascular and plasma-cell types of giant lymph node hyperplasia of the mediastinum and other locations. *Cancer* 1972; 29(3): 670–83.
8. *Dham A, Peterson BA*. Castleman disease. *Curr Opin Hematol* 2007; 14(4): 354–9.
9. *Casper C*. The aetiology and management of Castleman disease at 50 years: Translating pathophysiology to patient care. *Br J Haematol* 2005; 129(1): 3–17.
10. *Shah D, Darji P, Lodha S, Bolla S*. Unicentric Castleman's disease of abdomen. *J Radiol Case Rep* 2013; 7(3): 26–33.
11. *Saeed-Abdul-Rahman I, Al-Amri AM*. Castleman disease. *Korean J Hematol* 2012; 47(3): 163–77.
12. *Talat N, Belgaumkar AP, Schulte K*. Surgery in Castleman's disease: A systematic review of 404 published cases. *Ann Surg* 2012; 255(4): 677–84.
13. *Bucher P, Chassot G, Zufferey G, Ris F, Huber O, Morel P*. Surgical management of abdominal and retroperitoneal Castleman's disease. *World J Surg Oncol* 2005; 3: 33.
14. *Herrada J, Cabanillas F, Rice L, Manning J, Pugh W*. The clinical behavior of localized and multicentric Castleman disease. *Ann Intern Med* 1998; 128(8): 657–62.

Received on September 15, 2015.

Revised on November 24, 2015.

Accepted on November 25, 2015.

Online First March, 2016.